

VARICOCELE IN ADOLESCENTS: A REVIEW AND GUIDELINE FOR THE DAILY PRACTICE

R. Waalkes, I. F. Manea and J. M. Nijman.

Department of Urology. University Medical Center Groningen. University of Groningen. Groningen. The Netherlands.

Summary.- OBJECTIVES: Varicocele in adolescent men is one of the most challenging topics in pediatric urology. What should be considered as a good indication for treatment and at what age? Does treatment improve fertility? Can we wait? What is the best surgical and minimal invasive treatment? To answer these questions we provide a guideline to use in daily practice.

METHODS: We performed a search of the English literature of the last ten years through the Pub Med database using the following key words "varicocele", "diagnosis", "treatment", "fertility" and "adolescent". We then summated and compared the results of these studies.

CONCLUSION: Adolescents with varicocele need regular follow-up including clinical examination and ultrasound measurements of the testis. Those with a persistent discrepancy between left and right testis size of more than 20% over a period of 12 months and those with pain need varicocelectomy independent of patient age, Tanner stage or varicocele size. The peak retrograde flow (PRF) seems to be a good diagnostic non-invasive tool in the follow-up and can be of help to select patients for surgery. $PRF \geq 38$ cm/s in combination with testicular asymmetry $\geq 20\%$ is a reason for surgery independent of age, Tanner stage or varicocele size. $PRF < 30$ cm/s in combination with testicular asymmetry $< 20\%$ should be followed annually. In case of worsening PRF or asymmetry surgery must be performed. Patients suitable for conservative management should be followed until semen analysis is possible. We present a flow-chart to use in the management of adolescent varicocele. The best results of varicocele treatment are obtained with microscopic subinguinal and laparoscopic lymphatic sparing techniques as shown in a meta-analysis performed in this review.

Keywords: Adolescent. Varicocele. Treatment. Management.

CORRESPONDENCE



Rutger Waalkes
Koninginnelaan, 46
9717 BW Groningen
(The Netherlands).

waalkes.r@gmail.com

Accepted for publication: July 26th, 2012

Resumen.- OBJETIVO: El varicocele en el adolescente es uno de los temas más difíciles en Urología pediátrica. ¿Cuál debería considerarse una buena indicación de tratamiento y a qué edad? ¿Mejora la fertilidad con el tratamiento? ¿Podemos esperar? ¿Cuál es el mejor tratamiento quirúrgico y mínimamente invasivo? Para contestar a estas preguntas ofrecemos una guía clínica para la práctica diaria.

MÉTODOS: Realizamos una búsqueda en Pub Med de la literatura en habla inglesa de los últimos diez años

utilizando las siguientes palabras clave "varicocele", "diagnóstico", "tratamiento", "fertilidad" y "adolescente". Después resumimos y comparamos los resultados de estos estudios.

CONCLUSIONES: Los adolescentes con varicocele necesitan un seguimiento regular incluyendo la medición del testículo por exploración física y ecografía. En aquellos en los que haya una discrepancia del tamaño de más del 20% entre el testículo izquierdo y el derecho durante un periodo de 12 meses y los que tengan dolor necesitan varicolectomía independientemente de la edad del paciente, el estadio de Tanner o el tamaño del varicocele. El pico de flujo retrógrado (PFR) parece ser una buena herramienta no invasiva en el seguimiento y puede ser de ayuda para seleccionar pacientes para cirugía. Un $PFR \geq 38$ cm/s en combinación con una asimetría testicular $\geq 20\%$ es un argumento para la cirugía independientemente de la edad, el estadio de Tanner o el tamaño del varicocele. Con un $PFR < 30$ cm/s en combinación con una asimetría testicular $< 20\%$ debería hacerse seguimiento anual. En caso de empeoramiento del PFR o de la asimetría se debe operar. Los pacientes aptos para manejo conservador deberían hacer seguimiento hasta que sea posible realizar un seminograma. Presentamos un algoritmo para el manejo del adolescente con varicocele. Los mejores resultados del tratamiento del varicocele se obtienen con las técnicas microscópicas subinguinales y las laparoscópicas con preservación de linfáticos como demuestra el metaanálisis realizado en esta revisión.

Palabras clave: Adolescente. Varicocele. Tratamiento. Manejo.

INTRODUCTION

The association between varicocele and male infertility and the improvement in semen quality after varicocele ligation has caused an increasing interest in the study of adolescent varicocele. The World Health Organization reported that varicoceles are found in 25.4% of men with abnormal semen, compared with 11.7% of men with normal semen (1). Varicocele correction in adult males improves not only spermatogenesis but also Leydig cell function and varicocele is now recognized as the most surgically correctable cause of male infertility.

It has been suggested to treat varicoceles in adolescence in order to obtain the best results in adulthood. But not all men with varicoceles are infertile; 80% are asymptomatic and only 20% have fertility problems (1). So the question arises which adolescents need to be treated and at what age?

Because fertility can not be assessed in most young patients, other criteria are needed.

We studied the literature of the last 10 years in Pub Med in order to examine and compare the latest developments in diagnosis, indications and managements of varicocele in the adolescent male. Key words: varicocele, diagnosis, treatment, fertility and adolescent. We will try to provide a guideline for use in the daily clinical practice.

INCIDENCE

Varicocele is an unusual finding in boys younger than 10 years. Incidence increases rapidly in the age group 10 to 19 years to about 10-20% of adolescents, comparable with the incidence found in adults (2-5). It appears most frequent on the left side (90% of cases) (4). Bilateral varicoceles are regarded uncommon in adolescents have an incidence of 4%. Subclinical (present on ultrasound but not palpable) bilateral varicoceles are found in up to 40% of boys with grade 2 or 3 left varicocele. Making it comparable to the contemporary adult varicolectomy series with a median incidence of bilateral repair of 38% (6).

The varicocele prevalence is significantly increased in first-degree relatives (particularly brothers) of patients with known varicoceles. Neither varicocele grade nor bilaterality was predictive of inheritance in these first-degree relatives (7).

PATHOPHYSIOLOGY

Many theories have been proposed to explain the mechanism by which the disease disrupts normal testicular function and causes infertility in the adult male, but the true cause remains an enigma.

The predominance of left side varicocele is caused by the unique anatomy of the left testicular vein and is responsible for retrograde flow of blood into the internal spermatic vein and venous dilation. There are several theories that may explain the etiology of varicocele: higher venous pressure in the left renal vein, incompetence of the venous valve system and collateral venous anastomoses. The "nutcracker effect" is thought to occur when the renal vein is compressed between the superior mesenteric artery and aorta. Varicocele formation is caused by the resulting increased hydrostatic pressure (8).

There are multiple theories explaining the damaging effect of the varicocele on testicular function: hyperthermia (varicocele is associated

with elevated scrotal and testicular temperature and altered spermatogenesis), hyperperfusion (increased blood flow through the testis may affect spermatogenesis), hypoxia (stasis of blood could affect partial oxygen pressure and metabolism in the testis), reflux of adrenal metabolites (reflux of blood down the testicular vein and exposure of the testis to adrenal or renal metabolites), local testicular endocrine imbalance (multiple hormone modifications are subject for investigation with mixed results and need further research). The potent vasodilator nitric oxide is elevated in the dilated testicular veins found in varicoceles and therefore considered as another cause for the etiology of varicoceles (9-11).

More recent studies observed that HSPA2 (a heat shock protein) expression was down-regulated in adolescents with varicocele and oligozoospermia compared to controls and adolescents with varicocele have increased sperm nuclear DNA fragmentation which improved after surgery (12-14). Serum Inhibin B levels were also studied suggesting a negative correlation with varicocele presence, but the results of the studies were controversial (15-17). The use of these results in current urology practice needs further investigation in order to determine a marker of testicular damage and use this marker as an indication for treatment of adolescent varicocele.

The damaging effect of varicocele may be manifested as testicular growth failure and semen abnormalities. Testicular growth arrest induced by varicocele in young boys is well supported in the literature and is no longer questioned. Spermatogenesis is the most affected testicular function by varicocele as was found by Paduch and Niedzielski (18). They found significant lower total and progressive sperm motility, lower vitality and lower number of normal sperm form in boys with varicocele.

CLINICAL FINDINGS

In adolescence varicocele is usually asymptomatic and rarely causes pain. It may be noticed by the patient or his parents, or discovered by the pediatrician at a routine physical exam. Examination of the patient should be performed in a warm environment to relax the scrotum, first standing and than in supine position. Valsalva maneuver is needed in both standing and supine positions. The diagnosis depends upon the clinical finding of a collection of dilated and tortuous veins in the upright posture; the veins are more pronounced when the patient performs the Valsalva maneuver and disappear or diminish in the supine position. Especially right sided varicoceles which do not change its size so

dramatically in the supine position or at Valsalva must trigger the investigator to look for retroperitoneal tumors, kidney tumors or lymphadenopathy that can be the cause of these secondary varicoceles.

The following classification (according to the system of Dubin and Amelar) is used: Grade 0, subclinical varicoceles (not detectable on clinical examination; detected with use of ultrasound or venography); Grade I small varicocele (palpable only with a Valsalva maneuver); Grade II moderate size (palpable without the Valsalva maneuver); grade III, large (visible through the scrotal skin) (19).

Testicular volume and consistency must be recorded accurately in order to determine whether the growth of the ipsilateral testis is affected by the varicocele. The normal testis measures 1 cc to 2 cc in the prepubertal male (8). Several methods have been described to measure the size of the testis but the most useful are: comparative ovoids (Prader orchidometer), ring orchidometer (Takahara, Rochester) and ultrasound. Measurement of the volume with ultrasound is most accurate and reproducible (20,21).

Hypotrophy is stated if testicular size decrease is greater than 2 standard deviations from the normal growth curve. Because of individual variation in normal growth and development, some authors correlate testicular size more often with Tanner stage rather than chronological age. But in standard practice, the volume of the left testis is compared to the right using the formula: $\frac{(\text{right testis volume} - \text{left testis volume})}{\text{right testis volume}} \times 100\%$. In adolescents, a testis that is more than 2 ml or 10-20% smaller compared to the contralateral is considered hypotrophic.

MANAGEMENT

The most challenging aspect of managing adolescent varicocele is which criteria should be used to establish the indication for surgical treatment. After all, 80% of adult males with a varicocele will be fertile. Identifying adolescents who need varicocele correction have varied over time. Testicular disproportion, varicocele grade, semen analysis (Tanner V boys), symptomatic varicocele, presence of bilateral varicocele and peak retrograde flow on color Doppler ultrasound have all been subject of investigation to answer this question.

TESTICULAR DISPROPORTION

Testicular disproportion is historically considered to be the most important sign of testicular

damage in absence of the possibility to do routine semen analysis at this age. When possible, the leading factor for clinical management should be semen analysis (Tanner V boys). The negative correlation between testicular volume, sperm concentration and total motile sperm counts in adolescents is well supported by Diamond et al and supports the need for varicocele repair. Semen analyses were done in 57 Tanner stage V adolescent males at ages 14 to 20 years. Boys with testicular volume difference between affected left and normal right of 10-20% had an 11% chance of having a lower sperm count. If the testicular volume difference exceeded 20% the total motile sperm was abnormal in 59% (22).

The occurrence of "catch up growth" after varicocele repair is often described in the literature and is considered to be true by most physicians. The current dominant indication for surgery is a volume difference of more than 20% or of more than 2 ml between both testes, assessed by ultrasonography (23-26).

Recent studies revealed a potential catch-up testicular growth after conservative management. In a retrospective study of 14 patients with an initially significant difference in testicular volume (greater than 20%) who were managed conservatively, 7 experienced testicular catch-up growth (volume differential less than 20%) with a median follow up of 2.12 years (27). In another retrospective study of 71 boys, 38 (54%) initially had a 15% or greater volume differential and after nonsurgical follow-up with ultrasound for 2 years, 60 boys (85%) had testicular volume differentials in the normal range (less than 15%) (28). This last study was criticized for using a different formula for "volume differential" than normally used.

Poon et al investigated retrospectively 181 patients who were initially treated conservative. Serial volume measurements were obtained at a median interval of 12 months between the first and the most recent visit. Mean percent asymmetry for the group did not change with time. Among patients who initially had less than 20% asymmetry, 35% had 20% or greater asymmetry on follow-up and among those with 20% or greater asymmetry initially, 53% remained in that range. The authors advice to follow all patients with varicocele and testicular asymmetry closely, even those with no asymmetry as there is the possibility of worsening or new onset asymmetry (29).

In a recent prospective study, 54 consecutive pediatric patients were selected, with a median age of 14.5 years (range 13 to 16), who had left

varicocele and testicular volume discrepancy greater than 20%. Adolescents were divided into 2 groups, including 27 who underwent surgical correction with lymphatic sparing microsurgical varicocelectomy and 27 who were only observed. After surgery or at first observation patients were evaluated clinically and by ultrasound at 3, 6 and 12 months. They noted significant improvement in testicular volume with less than 20% disparity between the 2 gonads in 23 patients (85.2%) in the intervention group and in 8 controls (29.6%) after one year (30).

In a study that included 39 boys (11 to 19 years old) with clinical palpable varicocele, surgery was performed with at least 1 year of postoperative follow-up. Cayan et al observed that all 15 boys with a preoperative soft testis had normal testicular consistency postoperatively and of the 19 boys with preoperative testicular atrophy 10 (53%) did regain normal testicular growth, while 9 (47%) retained testicular volume loss after surgery. When comparing preoperative to postoperative increase in testicular volume according to age in all boys, the mean was significantly higher in boys younger than 14 years. However, in the adolescents older than 14 years, postoperative semen parameters and serum hormone values were significantly improved regardless of testicular volume (31).

Of 163 boys observed by Decastro et al (mean age 15.1 years, range 10 to 24) with left or bilateral varicoceles who demonstrated 10% asymmetry or greater preoperatively, 69% had achieved catch-up growth at last follow-up (mean follow-up 28 months). Catch-up growth following surgery is not statistically affected by age between 10 and 24, nor by Tanner stage (32).

This recent knowledge has lead us to question the historically absolute surgical indication for immediate surgical intervention if size discrepancy is greater than 20%. These studies indicate the need for close follow-up with serial ultrasound measurements to catch those who have a persistent or increasing size discrepancy after 1 year. Spontaneous catch-up growth is seen in studies in the first 2 years after diagnosis in up to 71% of patients (28,30,33). If the trend reveals a persistent testicular asymmetry of more than 20% after 12 months follow-up, surgery is indicated.

VARICOCELE SIZE

Varicocele size as a criterium for treatment is very questionable. Abnormal semen analysis or infertility does not correlate well with varicocele grade

in adults. In adolescents Diamond did not detect significant differences using semen analysis as a parameter for varicocele grade (22). Also, the grade of varicocele seems not to correlate with the presence or severity of testicular disproportion in adolescent boys as measured by scrotal ultrasound according to Alukal (34). In other studies, boys with a grade 3 varicocele have a higher risk of testicular growth arrest than those with a grade 2 varicocele (35,36). Kass observed a risk of bilateral testicular volume loss in grade 3 varicocele compared to normal controls and the presence of a grade I varicocele in adolescence appears to have no effect on normal testicular growth (37); although a recent study showed that 8 of 21 (38%) boys with varicocele grade I observed during a 5-year follow-up study had left testicular growth delay with or without an increasing grade of varicocele (38). As a result of these varying data varicocele size should not be the single indication for surgery.

SEMEN ANALYSIS

Diamond revealed a strong correlation between testicular growth arrest and semen analyses. 59% of boys with a greater than 20% testicular volume differential had an abnormal total mobile sperm count. At volume differentials of 10-20%, 11% were abnormal and two thirds had normal mobile sperm counts (22). However, semen analysis in adolescent boys is not usually considered practical from a psychological and ethical point of view. Unfortunately there are not yet standard norms for adolescent semen analysis. This needs further investigation (39).

SYMPTOMATIC VARICOCELE

Pain is rarely encountered in adolescents with varicocele. In one study 26 patients of 38 showed complete relief of pain six months after surgery. There was no correlation between grade of varicocele, hormonal values, type of surgery and relief of symptoms (40). There is clinical evidence that relief of pain is strictly correlated to the treatment of varicocele in the majority of cases. For this reason, a symptomatic varicocele should be treated surgically.

BILATERAL VARICOCELE

Glassberg and Ruslan found subclinical right sided varicoceles in 40.2% of their patients using Doppler ultrasound. These findings are similar to the findings in adults and contrary to what some pediatric urologists perceive. They do not operate subclinical varicoceles, but in case of borderline left varicoceles

the presence of a varicocele at the right side might tip the balance toward surgery. The asymmetry caused by growth arrest on the left side may be underestimated because of growth arrest of the right testicle (6).

PEAK RETROGRADE FLOW ON COLOR DOPPLER ULTRASOUND OF THE SPERMATIC CORD

In a recent study, Kozakowski et al revealed that all patients with the combination of an initial peak retrograde flow (PRF) of 38 cm per second or greater and 20% or greater asymmetry had progressive asymmetry at follow-up examination. For this reason the combination of $PRF \geq 38$ cm/s and $\geq 20\%$ asymmetry is an indication for surgery. $PRF \geq 30$ cm/s should be a reason to a meticulous follow-up as there is a great likelihood of persistent or new onset asymmetry. Patients with a $PRF < 30$ cm/s are less likely to require surgery and can be followed with ultrasound and clinical examination annually or every 2 years (41).

Poon et al found in a retrospective study of 181 patients that boys with a $PRF \geq 38$ cm/s on duplex ultrasound in association with 20% or greater asymmetry, spontaneous catch-up growth is unlikely to occur (29,33).

Korets et al advise to use the peak retrograde flow to identify boys with less than 15% testicular asymmetry at presentation who are at a higher risk for progressive testicular asymmetry. $PRF \geq 30$ cm/s is a risk factor to develop progressive asymmetry in boys with initially less than 15% asymmetry (77% worsened). The progression usually takes place in the first 2 years. Boys with $PRF < 30$ cm/s are less likely to develop asymmetry (32% worsened) but when it develops, it generally does so beyond 2 years. The authors therefore stress the importance of extended follow-up (42).

RECOMMENDATIONS

Adolescents with varicocele need regular and prolonged follow-up including clinical examination and ultrasound measurements of the testis. Those with a persistent discrepancy between left and right testis of more than 20% over a period of 12 months and those with pain need varicocelectomy independent of patient age or Tanner stage. The peak retrograde flow (PRF) seems to be a good diagnostic non-invasive tool in the follow-up and can be helpful to sort out patients for surgery. The following flow-chart (Figure 1) can be used to determine the indication for surgery. We

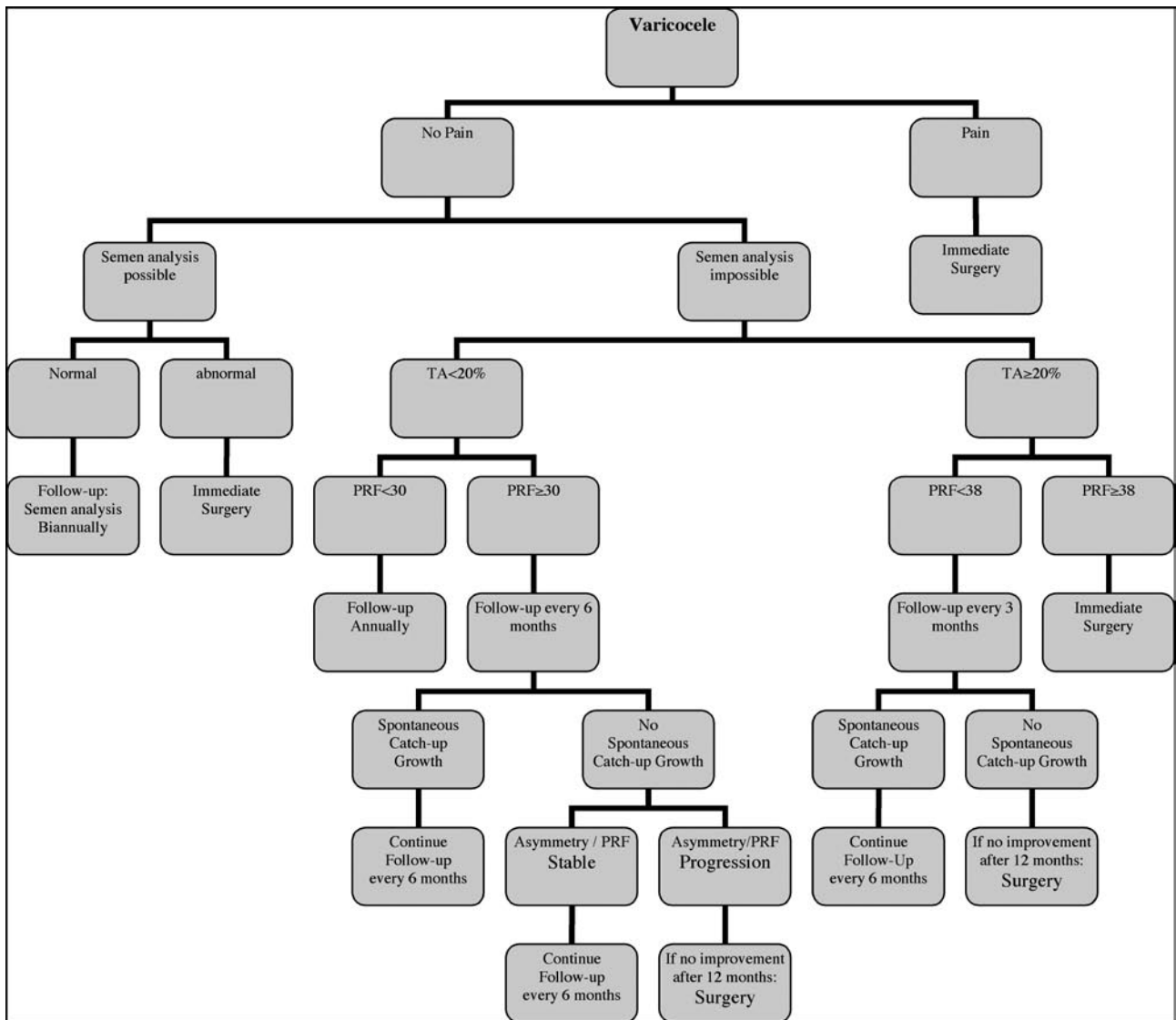
incorporated the peak retrograde flow: although in the literature only a few groups use this routinely, we believe that the extensive research they performed in large populations justifies this choice.

PRF \geq 38 cm/s in combination with testicular asymmetry \geq 20% is a reason for surgery independent of age, Tanner stage or varicocele size. PRF $<$ 30 cm/s in combination with testicular asymmetry $<$ 20% should be followed annually. In case of worsening PRF or asymmetry surgery must be performed. Patients who stay stable and suitable for conservative management should be followed until semen analysis is possible. The quality of the semen should be the leading indication whether to perform surgery or not in these asymptomatic patients.

TREATMENT OF THE VARICOCELE

Different approaches to stop retrograde blood flow in the internal spermatic vein(s) are available. The veins may be ligated at different levels through open or laparoscopic techniques: retroperitoneal (Palomo), inguinal (Ivanissevich) or subinguinal.

The risks for any of these techniques include hydrocele formation, damage to the vas, testicular atrophy and recurrence. Recently endovascular embolization techniques using the antegrade (pampiniform plexus) or retrograde (femoral vein) route are performed.



TA: Testicular asymmetry in percentage PRF: Peak Retrograde Flow in cm per second

FIGURE I. FLOW-CHART CONCERNING THE MANAGEMENT OF ADOLESCENT VARICOCELE.

Table I summarizes the latest surgical and minimal invasive series. The recurrence rate, hydrocele formation and hydrocele repair are mentioned (43-63). Table II shows a meta-analysis of the comparable series from Table I.

SURGICAL THERAPY

The traditional Palomo technique in which mass ligation is performed (open and laparoscopic) shows a low recurrence rate (1.9%) at the cost of

TABLE I. RESULTS AND COMPLICATIONS OF DIFFERENT TECHNIQUES.

Study	Technique	n	Mean follow-up in months	Artery spared	Lymph. spared	Recurrence	Hydrocele	Hydrocele repair
Misseri (43)	-Inguinal	28	25.5	Yes	Yes	14.0%	14.3% (4/28)	7.1% (2/28)
	-Palomo	67		No	No	3.0%	28.4% (19/67)	10.5% (7/67)
Feber (44)	-Palomo	233	17.4	No	No	3.9%	29.2% (68/233)	5.2% (12/233)
Oswald (45)	-Palomo using isosulfan blue	28	14	No	Yes	0%	0%	0%
Cohen (46)	-Laparoscopic	40	19.5	Yes	No	17%	12.5% (5/40)	0%
Esposito (47)	-Laparoscopic	30	26	Yes	No	6.6%	6.6% (14/211)	1.4% (3/211)
	-Laparoscopic	181		No	No	1.6%		
Mendez (48)	-Laparoscopic	156	67.2	No	No	1.9%	13.5% (21/156)	7.1% (11/156)
Pini Prato (49)	-Laparoscopic	41	15	No	No	2.4%	34,1% (14/41)	12,2% (5/41)
Hassan (50)	-Laparoscopic	79	20.7	No	No	1.3%	22.8% (18/79)	11.4% (9/79)
Glassberg (51)	-Laparoscopic	174	26.1	Yes	Yes	2.9%	3.4% (6/174)	2.3% (4/174)
	-Laparoscopic	88		Yes	No	4.5%	11.4% (10/88)	6.8% (6/88)
Kocvara (52)	-Laparoscopic using optical magnification	104	17	Yes	Yes	6.7%	1.9% (2/104)	NA
	-Traditional laparoscopic	71		32 Yes 39 No	No	8.9%	16.9% (12/71)	NA
Yaman (53)	-Subinguinal microsurgical	61	8.0	Yes	Yes	1.6%	0.0%	0.0%
Schiff (54)	-Subinguinal-microsurgical	97	10.1	Yes	Yes	0.0%	2.0% (2/97)	1.0% (1/97)
Vanderbrink (55)	-Subinguinal-microsurgical	31	24	Yes	Yes	3.2%	0.0%	0.0%
	-Laparoscopic	28		No	Yes	0.0%	3.6% (1/28)	3.6% (1/28)
Riccabona (56)	-Laparoscopic	19	52	Yes	No	10.5%	15.7% (3/19)	5.3% (1/19)
	-Inguinal-microsurgical	21		Yes	Yes	14.3%	0.0%	0.0%
	-Palomo	32		No	No	0.0%	12.5% (4/32)	12.5% (4/32)
	-Mod. Palomo using isosulfan blue	56		No	Yes	1.8%	0.0%	0.0%
Alqahtani (57)	-Retrograde percutaneous sclerotherapy	39	22	-	-	11.0%	0.0%	0.0%
Granata (58)	-Retrograde percutaneous sclerotherapy	86	31	-	-	8.0%	0.0%	0.0%
Stom (59)	-Retrograde percutaneous sclerotherapy	21	9	-	-	9.0%	0.0%	0.0%
Mazzoni (60)	-Antegrade sclerotherapy	65	9	-	-	7.4%	0.0%	0.0%
Mazzoni (61)	-Antegrade sclerotherapy	44	4	-	-	4.5%	0.0%	0.0%
Ficcara (62)	-Antegrade sclerotherapy	45	12	-	-	2.2%	0.0%	0.0%
Zaup (63)	-Antegrade sclerotherapy	88	11	-	-	7.0%	0.0%	0.0%

a very high hydrocele development, up to 34,1% found by Cohen. The modified Palomo technique by Oswald and Riccabona (lymphatic sparing using isosulfan blue) had an equally low recurrence rate of 1,2% and no hydrocele formation (43-45,56).

Laparoscopic varicocele ligation has gained popularity over the last years and is easily performed by surgeons familiar with laparoscopic technique. Success and complications rates are similar to the open Palomo repair. In a review by Barroso et al the results of varicocelectomy by the Palomo procedure in children and adolescents showed no statistical difference in the rate of hydrocele formation between the open Palomo and laparoscopic Palomo groups (64). The rate of hydrocele is high (7.7%) with the classical Palomo technique and seems to increase with extended follow-up. These data suggest that the hydrocele rate is underestimated in most of the studies with shorter follow-up. Artery sparing techniques reduce significantly the rate of hydrocele development. This artery sparing procedure may spare lymphatic branches adherent to the spermatic artery and reduces the rate of postoperative hydrocele development. The rate of varicocele recurrence seems similar in this review by Barosso et al (3% to 4%) in classical Palomo and modified (artery sparing) Palomo techniques. According to their data, testicular catch-up growth was similar between the modified (54.7%) and classical Palomo (66.7%) groups.

This is in contrast with the persistence rate of varicoceles of 17% after laparoscopic repair with preservation of the testicular artery found by Cohen et al (46). The testicular artery was identified and preserved with the aid of a Doppler-flow transducer. Ligation of internal epigastric veins was not associated with a decrease in the persistence of varicocele. Also, Esposito et al found a high recurrence in patients with artery sparing procedures comparing to Palomo's technique (6.6% versus 1.6%). In these patients the venography showed residual internal spermatic veins that probably had not been sectioned during surgery. In patients operated with Palomo's technique who had recurrence, the venography showed a recurrence through the deferential veins (47).

Recent studies concerning the laparoscopic Palomo using mass ligation showed hydrocele occurrence of 13.5% up to 34.1%. In these studies there is also a trend in finding more hydroceles after longer follow-up which may indicate that in many studies the hydrocele rate is underestimated due to short follow-up. Most hydroceles are found within 6 months after surgery, but they are found up to 2 years following surgery (48-50).

Different laparoscopic lymphatic sparing approaches in order to prevent hydrocele formation were described. When comparing lymphatic sparing procedures with non-lymphatic sparing procedures, Glassberg et al found that lymphatic sparing surgery was associated with a decreased incidence of postoperative hydrocele (3.4% vs 11.4%) with no significant difference in incidence of persistent or recurrent varicocele (51).

Kocvara et al concluded that intratesticular edema after non-lymphatic sparing varicocelectomy is most likely responsible for the increase in testis size and mistakenly seen as catch-up growth. They found testicular hypertrophy due to edema occurred less frequently after laparoscopic lymphatic sparing varicocelectomy, thus stating that catch-up growth can only be accurately assessed in the lymphatic spared repair (52,65).

These findings were contested by Poon et al in a retrospective study of 136 boys who had 10% or greater preoperative testicular asymmetry and underwent either a laparoscopic non-lymphatic sparing or laparoscopic lymphatic sparing varicocelectomy. There was no significant difference between the groups in regard to catch-up growth (51.7% vs 66.3%) after a mean follow-up of 24,7 months (66).

In a retrospective review of 92 adolescents Diamond et al compared results of different surgical approaches for treatment of varicocele. The low inguinal approach appeared to be the least successful. The laparoscopic technique (clipping and division of the entire spermatic vascular plexus) was most successful (100%) but showed the highest hydrocele rate (32%). The success rate of the subinguinal technique (88%) was intermediate between the more successful supra-inguinal and less successful inguinal approaches. Incorporating microsurgery had no effect on success rates but reduced the hydrocele formation to nil (70).

When selecting a surgical technique, the optimal procedure should be the one with the best results, the lowest failure rate and the fewest complications. Laparoscopic or open lymphatic sparing varicocelectomy is preferable to an open or laparoscopic Palomo repair that does not preserve the lymphatics. It has a significantly lower incidence of postoperative hydroceles and still maintains a low incidence of persistence/recurrence. In general it is advisable to preserve the artery in patients who have undergone previous inguinal surgery to minimal the risk of developing testicular atrophy.

Artery sparing technique could miss ligating small venous collaterals that are intimately attached to the artery and could explain a higher recurrence rate reported by some authors. The advantage of laparoscopy is the possibility to treat bilateral varicoceles or other intra-abdominal pathological conditions in the same surgery.

The use of microscopic magnification in an inguinal or subinguinal approach allows identification of the testicular artery, lymphatics and small venous channels and provides the best opportunity for artery sparing. Therefore, this approach results in a significant decrease in the incidence of hydrocele formation, testicular artery injury and varicocele recurrence. Inguinal or subinguinal approaches in children are potentially more difficult because of the reduced size of the internal spermatic veins and lymphatics and a diminished arterial pulse. An arterial injury at this level can lead to testicular atrophy. Another important consideration regarding varicocelectomy technique in adolescents is future vasectomy. Vasectomy in men who have undergone mass ligation varicocelectomy is more likely to result in testicular atrophy suggesting the need for an arterial sparing technique.

MINIMAL INVASIVE TECHNIQUES

Retrograde percutaneous embolization or scleroses of the internal spermatic vein in adolescents have been used to treat varicocele under local anesthesia on an outpatient basis. Procedural risks include pampiniform phlebitis, venous thromboembolism, failure of procedure, recurrence of varicocele and infection. The pediatric vascular interventional team from Montreal Canada states an 11% failure or recurrence rate, 4 because of persistent or recurrent varicocele and 2 because of technical failure. There were no major complications and no secondary hydrocele in the 39 procedures (57).

Retrograde percutaneous sclerotherapy was feasible in 72 of 86 (84%) patients enrolled in a study by Granata et al. The procedure was successful in 66 out of 72 (92%) patients (phlebography was repeated in five out of eight patients, in whom first attempt was ineffective and was feasible and successful in two of them). Therefore the overall success rate of 86 patients was 76%. Median length of follow-up was 31 months. During follow-up, 5 (8%) patients relapsed. Pampiniform phlebitis was observed in 11 (14%) cases. Neither late hydrocele nor other complications were observed (58).

Antegrade sclerotherapy is a new treatment for adolescents. It is minimally invasive, cost effective

and can be performed under local anesthesia. The collaboration of the patient in performing Valsalva is needed during injection of the sclerosing substance, thereby excluding very young or frightened patients. The procedure is not associated with subsequent hydrocele, but it can lead to the major complication of testicular necrosis. After a mean follow-up of 9 months, Mazzoni found a success rate after antegrade sclerotherapy of 92.6% in 65 patients (20 after failure of retrograde sclerosis or other surgery) (60). In another study of 44 antegrade sclerotherapy cases there was no hydrocele formation and a recurrence rate of 4.5% (61). Ficarra et al performed antegrade scrotal sclerotherapy in 45 consecutive adolescents. No patient required general anaesthesia during the treatment. No intraoperative complication was recorded and all patients were discharged within 4 hours. No complications were observed during the follow-up (12 months) and only 1 patient had reflux persistence (2.2%) (62). In a 88 adolescent series Zaupa noticed persisting varicocele in 7%. No hydroceles developed after a mean follow-up of 11 months (63).

However, studies involving retrograde or antegrade percutaneous sclerotherapy do not have results concerning testicular catch-up growth. The inclusions criteria were different compared to the surgical series (varicocele grade was the main criterium and few patients with testicular hypotrophy were included). The follow-up was shorter and focused only on technical success rates of the procedure.

The technique of percutaneous embolization and sclerotherapy represents an additional treatment option of the adolescents. It is not technically feasible in all cases and because of the relatively small caliber of the adolescent venous system the potential for vascular complications is higher at this age. The recurrence rate seems higher in sclerotherapy than in the surgical techniques (Table II).

CONCLUSION

Adolescents with varicocele need regular and prolonged follow-up including clinical examination and ultrasound measurements of the testis. Those with a persistent discrepancy between left and right testis of more than 20% over a period of 12 months and those with pain need varicocelectomy independent of patient age, Tanner stage or varicocele size. The peak retrograde flow can be helpful to sort out patients suitable for surgery. $PRF \geq 38$ cm/s in combination with testicular asymmetry $\geq 20\%$ is a reason for surgery independent of age, Tanner stage or varicocele size. $PRF < 30$ cm/s in combination with testicular

TABLE II. META-ANALYSIS REGARDING RECURRENCE AND COMPLICATIONS.

<i>Technique</i>	<i>n</i>	<i>Recurrence</i>	<i>Hydrocele</i>	<i>Hydrocele repair</i>
-Palomo (43, 44, 56)	565	1.9% (11/565)	16.1% (91/565)	4.1% (23/565)
-Palomo: Lymphatic sparing using isosulfan blue (43, 56)	84	1.2% (1/84)	0.0%	0%
-Subinguinal (using microscopic magnification) (53, 54, 55)	184	1.1% (2/184)	1.1% (2/184)	0.5% (1/184)
-Laparoscopic (Artery and Lymphatic <u>not</u> Spared) (48, 49, 50)	267	1.9% (5/267)	19.9% (53/267)	9.4% (25/267)
-Laparoscopic (Artery Spared) (46, 51, 56)	147	8.8% (13/147)	12.3% (18/147)	8.8% (13/147)
-Laparoscopic (Artery <u>and</u> Lymphatic Spared) (51, 52)	278	4.3% (12/278)	2.9% (8/278)	NA
-Retrograde Sclerotherapy (57, 58, 59)	146	8.9% (13/146)	0.0%	0.0%
-Antegrade Sclerotherapy (60, 61, 62, 63)	242	5.8% (14/242)	0.0%	0.0%

asymmetry <20% should be followed annually. In case of worsening PRF or asymmetry surgery must be performed. Patients suitable for conservative management must be followed until semen analysis is possible.

The quality of the semen should be the leading indication to perform surgery in the asymptomatic patient. The flow-chart in this review can be used to determine the indication for surgery.

Various surgical and non-surgical treatments are available which all have specific advantages and disadvantages concerning recurrence and complications. The best results are obtained with microscopic subinguinal and laparoscopic lymphatic sparing techniques (Table I and II).

The traditional Palomo technique, whether open or laparoscopic, offers a low recurrence rate at the cost of a (too) high hydrocele formation rate. Surgeons experience and availability of equipment determines to a great extent the choice and outcome of the treatment. In general, a lymphatic sparing technique should be used and in case of earlier surgery of the testis or groin the artery must be spared to prevent loss of a testicle as a result of ischemia. Sclerotherapy offers an alternative treatment with slightly higher recurrence rate. Data concerning catch-up growth after sclerotherapy have not been published.

REFERENCES AND RECOMMENDED READINGS (*of special interest, **of outstanding interest)

- *1. World Health Organization. The influence of varicocele on parameters of fertility in a large group of men presenting to infertility clinics. *Fertil Steril* 1992;57:1289-93.
2. Kumanov P, Robeva RN, Tomova A. Adolescent varicocele: who is at risk? *Pediatrics*. 2008;121:e53-7.
3. Akbay E, Cayan S, Doruk E, Duce MN, Bozlu M. The prevalence of varicocele and varicocele-related testicular atrophy in Turkish children and adolescents. *BJU Int*. 2000;86:490-3.
4. Niedzielski J, Paduch D, Raczynski P. Assessment of adolescent varicocele. *Pediatr Surg Int*. 1997;12:410-3.
5. Oster J. Varicocele in children and adolescents. An investigation of the incidence among Danish school children. *Scand J Urol Nephrol*;1971;5:27-32.
6. Glassberg KI, Korets R. Update on the management of adolescent varicocele. *F1000 Med.Rep*. 2010;2, pii:25
7. Raman JD, Walmsley K, Goldstein M. Inheritance of varicoceles. *Int J Urol*. 2007;14(12):1080-3. *Urology*. 2005;65:1186-9.
8. Paduch DA, Skoog SJ. Current Management of Adolescent Varicocele. *Rev. Urol*. 2001;3:120-133
9. Türkyilmaz Z, Gülen S, Sönmez K, Karabulut R, Dinçer S, Can Ba_aklar A, Kale N. Increased nitric oxide is accompanied by lipid oxidation in adolescent varicocele. *Int J Androl*. 2004;27:183-7.

10. Romeo C, Ientile R, Impellizzeri P, Turiaco N, Teletta M, Antonuccio P, et al. Preliminary report on nitric oxide-mediated oxidative damage in adolescent varicocele. *Hum Reprod.* 2003;18:26-9.
11. Santoro G, Romeo C, Impellizzeri P, Ientile R, Cutroneo G, Trimarchi F, et al. Nitric oxide synthase patterns in normal and varicocele testis in adolescents. *BJU Int.* 2001;88:967-73.
12. Lima SB, Cenedeze MA, Bertolla RP, Filho PA, Oehninger S, Cedenho AP. Expression of the HSPA2 gene in ejaculated spermatozoa from adolescents with and without varicocele. *Fertil Steril.* 2006;86:1659-63.
13. Bertolla RP, Cedenho AP, Hassun Filho PA, Lima SB, Ortiz V, Srougi M. Sperm nuclear DNA fragmentation in adolescents with varicocele. *Fertil Steril.* 2006;85:625-8.
- *14. Lacerda J, Del Giudice P, Ferreira da Silva B, Nichi M, Fariello R, Fraietta R et al.; Adolescent varicocele: improved sperm function after varicocelectomy. *Fertil Steril.* 2011; 95: 994-9
15. Basar MM, Kisa U, Tuglu D, Kacmaz M, Basar H. The effect of varicocele on seminal plasma and serum inhibin-B levels in adolescent and adult men. *Int Urol Nephrol.* 2010;42:47-51.
16. Romeo C, Arrigo T, Impellizzeri P, Manganaro A, Antonuccio P, Di Pasquale G, et al. Altered serum inhibin b levels in adolescents with varicocele. *J Pediatr Surg.* 2007;42:390-4.
17. Türkyılmaz Z, Karabulut R, Sönmez K, Demiroullari B, Ozen O, Moraliolu S, et al. Inhibin B levels in peripheral vein do not correlate with inhibin B levels in the spermatic vein in adolescents with varicocele. *Arch Androl.* 2006;52:325-8.
18. Paduch DA, Niedzielski J. Semen analysis in young men with varicocele: preliminary study. *J Urol.* 1996;156:788-90.
- *19. Dubin L, Ameral R. Varicocele size and results of varicocelectomy in selected subfertile men with varicocele. *Fertil Steril* 1970;21:606-19.
- *20. Cayan S, Akbay E, Bozlu M, Doruk E, Yildiz A, Acar D, et al. Diagnosis of pediatric varicoceles by physical examination and ultrasonography and measurement of the testicular volume: using the prader orchidometer versus ultrasonography. *Urol Int.* 2002;69:293-6.
- *21. Diamond DA, Paltiel HJ, Di Canzio J, Zurakowski D, Bauer SB, Atala A, et al. Comparative assessment of pediatric testicular volume: orchidometer versus ultrasound. *Urol.* 2000;164:1111-4.
22. Diamond DA, Zurakowski D, Bauer SB, Borer JG, Peters CA, Cilento BG Jr, et al. Relationship of varicocele grade and testicular hypotrophy to semen. *J Urol.* 2007;178:1584-8.
23. Paduch DA, Niedzielski J. Repair versus observation in adolescent varicocele: a prospective study. *J Urol.* 1997;158:1128-1132.
24. Laven JS, Haans LC, Mali WP, te Velde ER, Wensing CJ, Eimers JM. Effect of varicocele treatment in adolescents: a randomized study. *Fertil. Steril.* 1992;58:756-762
25. Okuyama A, Nakamura M, Namiki M, Takeyama M, Utsunomiya M, Fujioka H et al. Surgical repair of varicocele at puberty: preventive treatment for fertility improvement. *J Urol.* 1988;139:562-564.
26. Haan LC, Laven JS, Mali WP, te Velde ER, Wensing CJ. Testis volumes, semen quality, and hormonal patterns in adolescents with and without varicocele. *Fertil. Steril.* 1991;56:731-736.
27. Preston MA, Carnat T, Flood T, Gaboury I, Leonard MP. Conservative management of adolescent varicoceles: a retrospective review. *Urology.* 2008;72:77-80.
28. Kolon TF, Clement MR, Cartwright L, Bellah R, Carr MC, Canning DA, et al. Transient asynchronous testicular growth in adolescent males with a varicocele. *J Urol.* 2008;180:1111-4; discussion 1114-5.
- **29. Poon SA, Gjertson CK, Mercado MA, Raimondi PM, Kozakowski KA, Glassberg KI. Testicular asymmetry and adolescent varicoceles managed expectantly. *J Urol.* 2010;183:731-4.
- *30. Spinelli C, Di Giacomo M, Lo Piccolo R, Martin A, Messineo A. The role of testicular volume in adolescents with varicocele: the better way and time of surgical treatment. *J Urol.* 2010;184(4 Suppl):1722-6.
- *31. Cayan S, Akbay E, Bozlu M, Doruk E, Erdem E, Acar D, Ulusoy E. The effect of varicocele repair on testicular volume in children and adolescents with varicocele. *J Urol.* 2002;168:731-4.
32. Decastro GJ, Shabsigh A, Poon SA, Laor L, Glassberg KI. Adolescent varicocelectomy-is the potential for catch-up growth related to age and/or Tanner stage? *J Urol.* 2009;181:322-7; discussion 327.
33. Van Batavia J, Salamon L, Woldu P, Raimondi P, Spencer B, Insel B, et al. Adolescent Varicocele: influence of Tanner Stage at presentation on the Presence, Development, Worsening and/or Improvement of Testicular Hypotrophy Without Surgical Intervention. *J.Urol.* 2010;184:1727-1732
34. Alukal JP, Zurakowski D, Atala A, Bauer SB, Borer JG, Cilento BG Jr, et al. Testicular hypotrophy does not correlate with grade of adolescent varicocele. *J.Urol.* 2005;174:2367-70, discussion 2370.
35. Zampieri N, Zuin V, Corroppolo M, Ottolenghi A, Camoglio FS. Relationship between varicocele grade, vein reflux and testicular growth arrest. *Pediatr Surg Int.* 2008;24:727-30.
- *36. Thomas JC, Elder JS. Testicular growth arrest and adolescent varicocele: does varicocele size make a difference? *J Urol.* 2002;168:1689-91; discussion 1691.
37. Kass EJ, Stork BR, Steinert BW. Varicocele in

- adolescence induces left and right testicular volume loss. *JU Int.* 2001;87:499-501.
38. Shiraishi K, Takihara H, Matsuyama H. Effects of grade 1 varicocele detected in the pediatric age-group on testicular development. *J Pediatr Surg.* 2009;44:1995-8.
 39. Zampieri N, Corroppo M, Zuin V, Cervellione RM, Ottolenghi A, Camoglio FS. Longitudinal study of semen quality in adolescents with varicocele: to treat or not? *Urology.* 2007;70:989-93.
 40. Zampieri N, Ottolenghi A, Camoglio FS. Painful varicocele in pediatric age: is there a correlation between pain, testicular damage and hormonal values to justify surgery? *Pediatr Surg Int.* 2008;24:1235-8.
 - **41. Kozakowski KA, Gjertson CK, Decastro GJ, Poon S, Gasalberti A, Glassberg KI. Peak retrograde flow: a novel predictor of persistent, progressive and new onset asymmetry in adolescent varicocele. *J Urol.* 2009;181:2717-22; discussion 2723.
 42. Korets R, Woldu SL, Nees SN, Spencer BA, Glassberg KI. Testicular Symmetry and Adolescent Varicocele-Does it Need Followup? *J Urol.* 2011;186:1614-1619
 - *43. Misseri R, Gershbein AB, Horowitz M, Glassberg KI. The adolescent varicocele. II: the incidence of hydrocele and delayed recurrent varicocele after varicoectomy in a long-term follow-up. *BJU Int.* 2001;87:494-8.
 44. Feber KM, Kass EJ. Varicoectomy in adolescent boys: long-term experience with the Palomo procedure. *J Urol.* 2008;180:1657-9; discussion 1659-60.
 45. Oswald J, Körner I, Riccabona M. The use of isosulphan blue to identify lymphatic vessels in high retroperitoneal ligation of adolescent varicocele-avoiding postoperative hydrocele. *BJU Int.* 2001;87:502-4.
 46. Cohen RC. Laparoscopic varicoectomy with preservation of the testicular artery in adolescents. *Pediatr Surg.* 2001;36:394-6.
 47. Esposito C, Monguzzi G, Gonzalez-Sabin MA, Rubino R, Montinaro L, Papparella A, et al. Results and complications of laparoscopic surgery for pediatric varicocele. *J Pediatr Surg.* 2001;36:767-9.
 48. Méndez-Gallart R, Bautista-Casasnovas A, Estevez-Martínez E, Varela-Cives R. Laparoscopic Palomo varicocele surgery: lessons learned after 10 years' follow up of 156 consecutive pediatric patients. *J Pediatr Urol.* 2009;5:126-31.
 49. Pini Prato A, MacKinlay GA. Is the laparoscopic Palomo procedure for pediatric varicocele safe and effective? Nine years of unicentric experience. *Surg Endosc.* 2006;20:660-4.
 50. Hassan JM, Adams MC, Pope JC 4th, Demarco RT, Brock JW 3rd. Hydrocele formation following laparoscopic varicoectomy. *J Urol.* 2006;175:1076-9.
 - *51. Glassberg KI, Poon SA, Gjertson CK, DeCastro GJ, Misseri R. Laparoscopic lymphatic sparing varicoectomy in adolescents. *J Urol.* 2008;180:326-30; discussion 330-1.
 - *52. Kocvara R, Dvořáček J, Sedláček J, Díte Z, Novák K. Lymphatic sparing laparoscopic varicoectomy: a microsurgical repair. *J Urol.* 2005;173:1751-4.
 53. Yaman O, Soygur T, Zumrutbas AE, Resorlu B. Results of microsurgical subinguinal varicoectomy in children and adolescents. *Urology.* 2006;68:410-2
 54. Schiff J, Kelly C, Goldstein M, Schlegel P, Poppas D. Managing varicoceles in children: results with microsurgical varicoectomy. *BJU Int.* 2005;95:399-402.
 55. VanderBrink BA, Palmer LS, Gitlin J, Levitt SB, Franco I. Lymphatic-sparing laparoscopic varicoectomy versus microscopic varicoectomy: Is there a difference? *Urol.* 2007;70:1207-10
 56. Riccabona M, Oswald J, Koen M, Lusuardi L, Radmayr C, Bartsch G. Optimizing the operative treatment of boys with varicocele: sequential comparison of 4 techniques. *J Urol.* 2003;169:666-8.
 57. Alqahtani A, Yazbeck S, Dubois J, Garel L. Percutaneous embolization of varicocele in children: A Canadian experience. *J Pediatr Surg.* 2002;37:783-5.
 58. Granata C, Oddone M, Toma P, Mattioli G. Retrograde percutaneous sclerotherapy of left idiopathic varicocele in children: results and follow-up. *Pediatr Surg Int.* 2008;24:583-7.
 59. Storm DW, Hogan MJ, Jayanthi VR; Initial experience with percutaneous selective embolization: A truly minimally invasive treatment of the adolescent varicocele with no risk of hydrocele development. *J Pediatr Urol* 2010; 6: 567-571
 60. Mazzoni G. Adolescent varicocele: treatment by antegrade sclerotherapy. *Pediatr Surg.* 2001; 36:1546-50.
 61. Mazzoni G, Spagnoli A, Lucchetti MC, Villa M, Capitanucci ML, Ferro F. Adolescent varicocele: Tauber antegrade sclerotherapy versus Palomo repair. *J Urol.* 2001;166:1462-4.
 62. Ficarra V, Sarti A, Novara G, Dalpiaz O, Galfano A, Cavalleri S, Artibani W. Modified antegrade scrotal sclerotherapy in adolescent patients with varicocele. *J Pediatr Surg.* 2004;39:1034-6.
 63. Zaupa P, Mayr J, Höllwarth ME. Antegrade scrotal sclerotherapy for treating primary varicocele in children. *BJU Int.* 2006;97:809-12.
 64. Barroso U Jr, Andrade DM, Novaes H, Netto JM, Andrade J. Surgical treatment of varicocele in children with open and laparoscopic Palomo technique: a systematic review of the literature. *J Urol.* 2009;181:2724-8.
 - *65. Kocvara R, Dolezal J, Hampl R, Pov_sil C, Dvo-

- ráček J, Hill M, Díte Z, et al. Division of lymphatic vessels at varicocelectomy leads to testicular oedema and decline in testicular function according to the LH-RH analogue stimulation test. *Eur Urol.* 2003;43:430-5.
- **66. Poon SA, Kozakowski KA, Decastro GJ, Gjertson CK, Glassberg KI. *J Pediatr Urol.* Adolescent varicocelectomy: postoperative catch-up growth is not secondary to lymphatic ligation. 2009;5:37-41.
67. Martino A, Zamparelli M, Cobellis G, Mastroianni L, Amici GJ One-trocar surgery: a less invasive videosurgical approach in childhood. *Pediatr Surg.* 2001;36:811-4.
68. Kaouk JH, Palmer JS. Single-port laparoscopic surgery: initial experience in children for varicocelectomy. *BJU Int.* 2008;102:97-9.
69. Hidalgo-Tamola J, Sorensen MD, Bice JB, Lendvay TS. Pediatric robot-assisted laparoscopic varicocelectomy. *J Endourol.* 2009;23:1297-300.
- **70. Diamond DA, Xuwu J, Cilento BG Jr, Bauer SB, Peters CA, Borer JG, et al. Varicocele surgery: a decade's experience at a children's hospital. *BJU Int.* 2009;104:246-9.